



Case Series

Primary Umbilical endometriosis - case series and review of clinical presentation, diagnosis and management

Vimee Bindra^{a,*}, Sowmya Sampurna^a, Sandesh Kade^b, Girija Shankar Mohanty^a,
Nori Madhavi^c, P. Swetha^a

^a Department of Obstetrics and Gynaecology, Apollo Hospital, Hyderabad, India

^b Department of Obstetrics and Gynaecology, Sunrise Hospitals, Solapur, India

^c Madhavi Scan Centre, Hyderabad, India



ARTICLE INFO

Keywords:

Endometriosis
Cyclical pain
Primary umbilical endometriosis
Omphalectomy
Villar's nodule
Pelvic endometriosis
Case series

ABSTRACT

Introduction: Umbilical endometriosis is the most common cutaneous form and is seen mostly secondary to surgical scar and rarely occurs as primary umbilical endometriosis. The objective of this retrospective case series evaluation is to report the presentation, diagnosis, and management of patients with primary umbilical endometriosis.

Presentation of cases: We present a retrospective, observational and descriptive review of cases presenting with primary umbilical endometriosis among Indian women managed in two private tertiary care centres between 2018 and 2020. Patients were assessed at the gynaecological outpatient department. We analysed age, parity, presenting symptoms and duration, associated symptoms, imaging, size of the lesion, associated pelvic endometriosis or any pelvic pathology, management, and histopathological diagnosis for confirmation in all four patients.

Discussion: The patients were aged between 25 and 31 years with an average of 28 years with no previous history of any abdominal surgeries. The mean duration of the symptoms presented in these cases was 25.5 months, with a range from 18 to 48 months. The diagnosis was made by clinical examination supported by imaging followed by complete surgical excision and confirmation on histopathology.

Conclusion: Primary umbilical endometriosis is a rare disease with a limited number of cases reported in the literature and should be included in the differential diagnosis if women present with umbilical lesions with cyclical pain. Diagnosis is clinical but can be aided by high resolution imaging such as Ultrasound (US) and Magnetic Resonance Imaging (MRI). Complete surgical excision is the treatment of choice.

1. Introduction

Endometriosis is defined as the presence of endometrial like tissue outside the uterus [1]. It is a complex symptomatic, pathobiological, multisystemic disease that affects women from menarche through menopause regardless of ethnic origin or social status [2,3]. Being a chronic recurrent disease it affects the quality of life of patients significantly. Globally the incidence of endometriosis is 10% among reproductive-age group, roughly affecting 190 million, out of which more than 26 million women are in India [4,5]. Though, endometriosis is commonly seen in ovaries, uterosacral and Pouch of Douglas (POD), presence of cutaneous endometriosis has been noticed in about <5.5% of all cases of endometriosis [2]. Umbilical endometriosis is the most

common cutaneous form [6]. It can be primary or secondary, with secondary umbilical endometriosis being more common and is seen mostly secondary to surgical scar [7].

Primary umbilical endometriosis develops in absence of any prior abdominal surgery. The exact prevalence is not known but the incidence is reported to be 0.5% - 1% of all extra genital endometriosis [8]. Primary umbilical endometriosis was described by Villar for the first time in 1886 [9]. When primary umbilical endometriosis is seen along with concurrent pelvic endometriosis the possible theory postulated is haematogenous or lymphatic spread and an isolated presentation could be because of metaplasia of urachal remnants [10].

The diagnosis is mainly clinical with women presenting with a bluish-purple, brown discolouration of the umbilicus associated with cyclical

* Corresponding author.

E-mail address: vimee.bindra@gmail.com (V. Bindra).

<https://doi.org/10.1016/j.ijscr.2022.107134>

Received 4 April 2022; Received in revised form 22 April 2022; Accepted 26 April 2022

Available online 30 April 2022

2210-2612/© 2022 The Authors. Published by Elsevier Ltd on behalf of IJS Publishing Group Ltd. This is an open access article under the CC BY-NC-ND license (<http://creativecommons.org/licenses/by-nc-nd/4.0/>).

swelling and pain. The presentation can vary in the presence of concurrent pelvic endometriosis. This heterogeneity in presentation can misguide the physicians and though clinicians are well versed with pelvic endometriosis, extra pelvic endometriosis is still an enigma and often the diagnosis is delayed [11].

Here, we have done a retrospective, observational and descriptive case series of four Primary Umbilical Endometriosis (PUE). We analysed demographic profile, presenting symptoms, imaging, associated pelvic pathology, management of these patients and follow up for 18 months.

2. Material and methods

We have done a retrospective, observational and descriptive evaluation of primary umbilical endometriosis cases managed in two private tertiary centres in India between 2018 and 2020. As this was a retrospective case series, no objection was obtained from ethics committee. The patients were assessed at the gynaecological outpatient department. We analysed age, parity, presenting symptoms and duration, associated symptoms, imaging, size of the lesion, associated pelvic endometriosis with staging of endometriosis done according to the revised American Society for Reproductive Medicine (rASRM) classification, any other pelvic pathology, its management, and histopathological diagnosis of four patients. This work has been reported in line with PROCESS Guideline 2020 [12]. Written informed consent was obtained from the patient for publication of this case report and accompanying images. A copy of the written consent is available for review by the Editor-in-Chief of this journal on request.

3. Results

The mean age of the four patients was 28 years, with the maximum age being 31 yrs. and the minimum age was 25 years. All the patients were nulliparous; none had a history of miscarriage or any other abdominal surgeries in the past.

The average duration of the symptoms was 25.5 months, with a range from 18 to 48 months (Table 1). (The presenting complaints were mainly cyclical umbilical pain(75%), one patient presented with continuous umbilical pain(25%). There was associated pelvic pain in 2 patients (50%). Cyclical colour change in the umbilicus was noted in 2 patients (50%) (Fig. 1).

Two of the patients had associated symptoms of menorrhagia (50%). The preoperative diagnosis was made mainly by clinical evaluation (100%). Confirmed by ultrasound (US) in 3 patients (75%) and by Magnetic Resonance Imaging (MRI) in one patient (25%).

The largest diameter of the lesion ranged from 1 to 3 cm (mean 1.67 cm). One patient (25%) had MRI with a lesion measuring 1.2 cm suggesting umbilical endometriosis with advanced stage pelvic endometriosis. Another patient underwent US showing an umbilical lesion of 3 cm suggestive of umbilical endometriosis with stage 3 endometriosis and fibroids. The other two patients underwent US with 1–1.5 cm lesions and were diagnosed with umbilical endometriosis (Fig. 2).

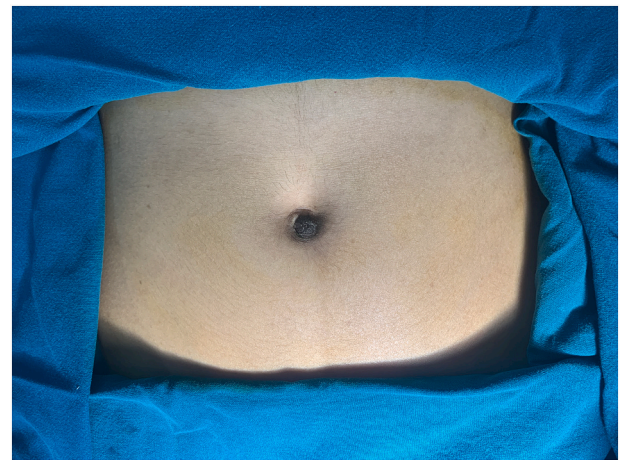


Fig. 1. Colour change in the umbilicus.

All patients had surgical excision of the umbilical lesion. Two patients had involvement up to rectus sheath, and resection was done with a free margin of 1 cm from the lesion with the closure of the umbilical defect performed by endometriosis excisional surgeon with vast experience in handling endometriosis at different locations (Figs. 3,4).

One patient had laparoscopic endometriosis excision and myomectomy, and one had laparoscopic excision of bilateral endometrioma and pelvic endometriosis. The other two patients also underwent laparoscopy to rule out pelvic endometriosis.

The operation time on an average was 60-90 min with minimal blood loss, not more than 50 ml in all the cases.

All the excised specimens were sent for histopathology. Diagnosis of endometriosis was confirmed by identifying endometrial glands and stroma and recent hemorrhage noted in the dermis with no evidence of malignancy. All patients had an uneventful postoperative period.

4. Discussion

Endometriosis can be broadly classified as pelvic and extra-pelvic endometriosis. Umbilical endometriosis is a form of extra-pelvic endometriosis. It is the most common cutaneous form and is termed as secondary umbilical endometriosis when it occurs secondary to a surgical scar and as primary umbilical endometriosis when the occurrence is spontaneous [2]. Villar, in 1886, described primary umbilical endometriosis for the first time [11]. Approximately 15% of primary umbilical endometriosis have coexistent Pelvic endometriosis.

The mean age of the patients presented to us was 28 years, which is below the age group of 35–38 years reported in the literature. A probable reason for the early onset may be modern lifestyle exposure to hormones and toxins causing metaplasia in younger age group [13].

Our findings in terms of mean duration of the symptoms, presenting complaints and the average diameter of the lesion were in the same

Table 1
Presentation and treatment of PUE cases.

| CASE | Age | Parity | Presentation | Duration of symptoms | Any previous surgeries | Imaging | Size of the lesion | Pelvic endometriosis | Histology | Associated pathology |
|------|-----|--------|--|----------------------|------------------------|---------|--------------------|----------------------|-----------|----------------------|
| 1 | 30 | 0 + 0 | Severe pelvic pain cyclical umbilical pain | 4 years | Nil | US | 3 × 3 cm | Stage III | Confirmed | Leiomyoma |
| 2 | 26 | 0 + 0 | Continuous pain | 2 years | Nil | US | 1 × 1.2 cm | Nil | Confirmed | Nil |
| 3 | 31 | 0 + 0 | Severe cyclic pain and cyclical colour change at umbilicus | 1 year | Nil | US | 1.5 × 1.2 cm | Nil | Confirmed | Nil |
| 4 | 25 | 0 + 0 | Cyclical pain and post menstrual brownish discharge from the umbilicus | 1 year 6 months | Nil | MRI | 1.2 × 0.9 cm | Stage IV | Confirmed | Nil |

US – Ultrasonography; MRI – Magnetic Resonance Imaging.

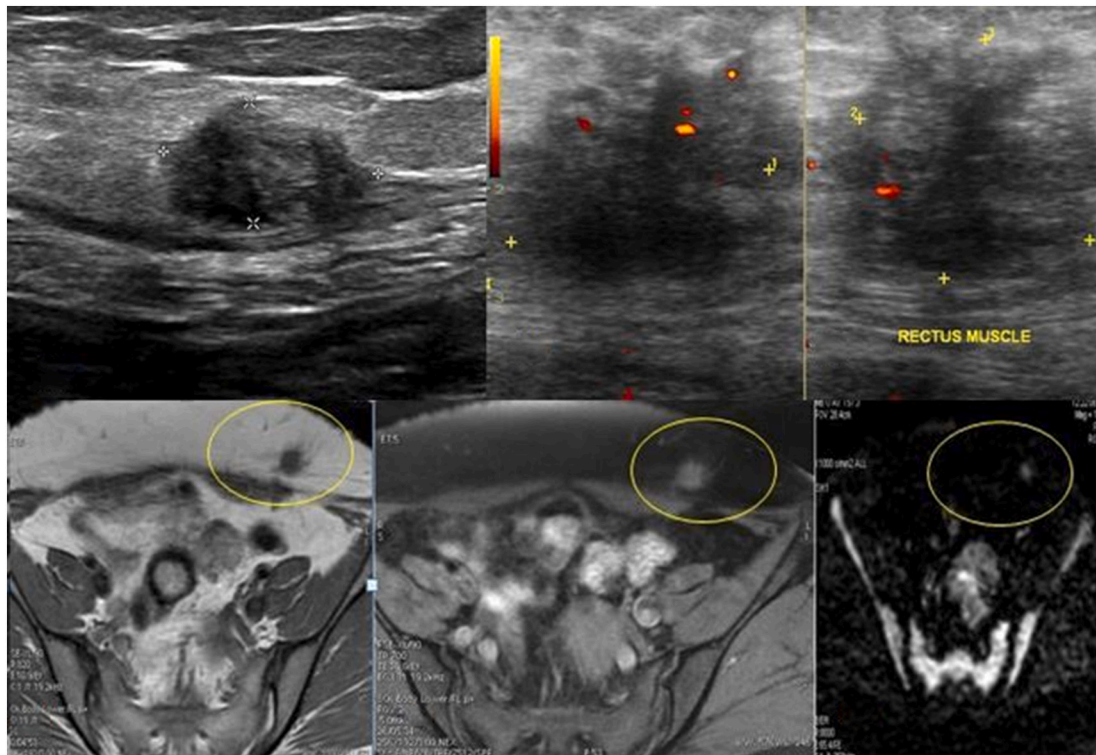


Fig. 2. USG TRANSVERSE image superior to the umbilicus reveals avascular, irregular hypoechoic mass with posterior acoustic shadowing. On colour doppler, mild internal vascularity seen.

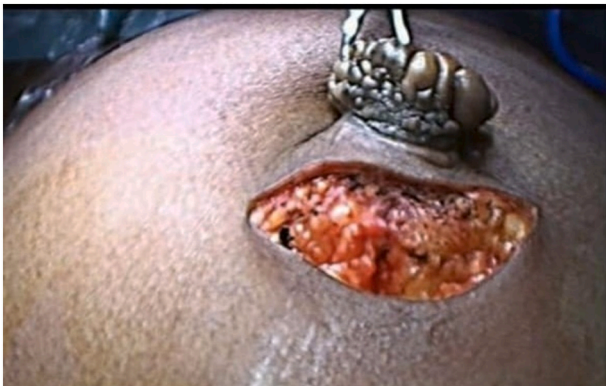

Fig. 3. Wide excision of umbilical endometriosis.

range stated in the literature. The average duration of symptoms stated was 21.1 months and in our case series its noted as 25.5 months. The presenting complaints were umbilical nodule with cyclical umbilical pain. The average diameter of the lesion was 3.02 cm [14] and we noticed it as 1.67 cm.

The diagnosis is primarily clinical with classic history of umbilical swelling with cyclical pain and bleeding. The role of imaging is to provide accurate diagnosis and precise information regarding the nodule size, involvement of surrounding structures and presence of concomitant pelvic endometriosis to aid in pre-surgical planning which is the definitive treatment. High Resolution imaging has high yield when combined with history and physical examination, without clinical history the imaging findings in isolation has less specificity with other differentials of umbilical nodules.

The appearance of cutaneous endometriosis, both scar and primary umbilical on imaging depends on the number of stromal and glandular elements, the amount of bleeding, phase of the patient's menstrual cycle

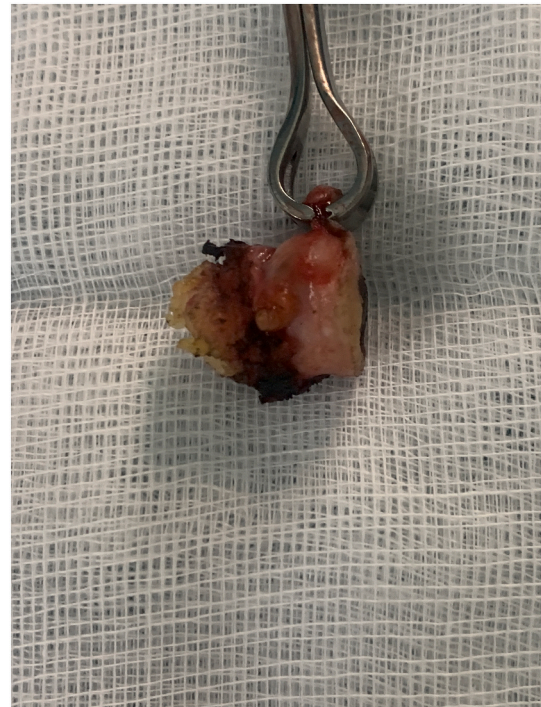

Fig. 4. Excised specimen.

and the chronicity of the process and associated inflammation.

Ultrasound (US) is the primary imaging modality to assess the umbilical endometriosis with magnetic resonance imaging (MRI) providing second line imaging in complementing ultrasound and in characterisation of complex lesions with concomitant pelvic involvement.

The imaging features reflect the underlying pathological changes. Most common manifestation on ultrasound is solid, nonhomogeneous hypoechoic mass with echogenic spots or thick echogenic strands that represent a fibrotic component. The pattern of echogenicity reflects the amount and distribution of haemorrhagic and fibrous tissue components. On colour doppler, there is internal vascularity with power doppler having higher sensitivity for low velocity flow [14].

The advantages of MRI to ultrasound makes it second line/problem solving modality. Tissue characterisation of MRI adds specificity by identifying hemorrhage associated with endometriotic lesions. Superb soft tissue contrast resolution aids in better delineation between muscles and abdominal subcutaneous tissues and infiltration of abdominal wall structures.

Imaging can also guide in differentiating other causes of umbilical swelling such as haemangioma, granuloma, melanocytic nevus, seboreh keratosis, granular cell tumour, umbilical hernia and umbilical polyps [13].

Among our 4 patients, 3 of them underwent ultrasound and one was diagnosed with stage 3 endometriosis with fibroids and 1 patient underwent MRI showed advanced stage pelvic endometriosis. Hence, it was useful to accurately and safely plan surgical resection in these patients.

The consensus about standard management of primary umbilical endometriosis is not developed due to the rarity of the disease [13,15].

The management options are:

Medical management widely used hormonal therapy like oral contraceptive pills, dienogest and GnRH antagonist have been mentioned in literature and have been effective in relieving the symptoms but disease progression is not halted by medical therapy so recurrence of symptoms and growth of lesions is the major drawback [16].

Surgical management options:

1. Omphalectomy -complete umbilical resection, with or without repair of the underlying fascia and peritoneum [17].
2. Omphalectomy -complete umbilical resection, with excision of associated pelvic endometriosis and fertility-enhancing surgery.
3. Local radical excision of the endometriotic nodule, sparing the umbilicus [18].

Complete excision of umbilical endometriosis aided by laparoscopy entails a complete excision, reduces recurrence and this also allows to treat concomitant pelvic endometriosis if any [19].

All our patients had surgical excision of the umbilical lesion with a 1 cm free margin and the umbilical defect was closed. Other associated pathology like pelvic endometriosis, fibroid and ovarian cysts were handled laparoscopically and confirmed by histopathology.

These patients have been followed up clinically every six months. Neither symptoms nor signs of local recurrence have been observed during the follow up for 18 months.

5. Conclusion

Primary umbilical endometriosis is a rare disease with a limited number of cases reported in the literature and should be included in the differential diagnosis if women present with umbilical lesions with cyclical pain. Diagnosis is clinical but can be aided by high resolution imaging such as US and MRI. Complete surgical excision is the treatment of choice.

Sources of funding

None.

Ethical approval

Institutional Ethics Committee- biomedical research.

No objection was obtained as this was a retrospective case series.

Consent

Written informed consent was obtained from the patient for publication of this case report and accompanying images. A copy of the written consent is available for review by the Editor-in-Chief of this journal on request.

Registration of research studies

None.

Provenances and peer review

Not commissioned, externally peer reviewed.

Guarantor

Dr. Vimee Bindra

CRedit authorship contribution statement

Dr. Vimee Bindra – study concept and design/writing the paper.
 Dr. Sowmya Sampurna – data collection.
 Dr. Sandesh Kade – data collection.
 Dr. Girija Shankar Mohanty – Data analysis/writing the paper.
 Dr. Nori Madhavi – Data collection.
 Dr. Swetha P – writing the paper.

Declaration of competing interest

All authors declare no conflicts of interest.

References

- [1] B. Eskenazi, M.L. Warner, Epidemiology of endometriosis, *Obstet. Gynecol. Clin. N. Am.* 24 (2) (1997) 235–258.
- [2] R. Victory, M.P. Diamond, D.A. Johns, Villar's nodule: a case report and systematic literature review of endometriosis externa of the umbilicus, *J. Minim. Invasive Gynecol.* 14 (2007) 23–32.
- [3] K. Kyamidis, V. Lora, J. Kanitakis, Spontaneous cutaneous umbilical endometriosis: report of a new case with immuno histochemical study and literature review, *Dermatol. Online J.* 17 (2011) 5.
- [4] K.T. Zondervan, D. Phil, M.D. Becker, et al., Endometriosis, review article, *N. Engl. J. Med.* 382 (1244) (2020) 56.
- [5] Endometriosis, WHO 2021 (March):2–7. Available from: <https://www.who.int/news-room/fact-sheets/detail/endometriosis#:~:text=Key,2021,facts,and,girls globally>. Accessed on February 25 th, 2022.
- [6] N. Palshtekar, Key practice points on endometriosis, *FOGSI. Integr.* (2019) 6–8.
- [7] S. Kodandapani, M.V. Pai, M. Mathew, Umbilical laparoscopic scar endometriosis, *J. Hum. Reprod. Sci.* 4 (3) (2011) 150–152.
- [8] F. Taniguchi, E. Hirakawa, Y. Azuma, et al., Primary umbilical endometriosis: unusual and rare clinical presentation, *Case Rep. Obstet. Gynecol.* 2016 (2016), 9302376.
- [9] B.D. Kjer, B.D. Kjer, J.J. Kjer, Primary umbilical endometriosis(PUE), *Eur. J. Obstet. Gynecol. Reprod. Biol.* 209 (2017) 44–45.
- [10] W.T. Teh, B. Vollenhoven, P.I. Harris, Umbilical endometriosis, a pathology that a gynecologist may encounter when inserting the verres needle, *Fertil. Steril.* 86 (6) (2006), 1764.e1-2.
- [11] R. Victory, M.P. Diamond, D.A. Johns, Villar's nodule: a case report and systematic literature review of endometriosis externa of the umbilicus, *J. Minim. Invasive Gynecol.* 14 (1) (2007) 23–32.
- [12] R.A. Agha, C. Sohrabi, G. Mathew, T. Franchi, A. Kerwan, N. O'Neill, for the PROCESS Group, The PROCESS 2020 guideline: updating consensus Preferred Reporting Of CasE Series in Surgery (PROCESS) guidelines, *Int. J. Surg.* (2020) 60 (article in press).
- [13] L. Capasso, V. Sciascia, G. Loiacono, et al., Case report primary subcutaneous umbilical endometriosis, *Case Rep. Rev. Lit.* 2020 (2020).
- [14] D. Makena, T. Obura, S. Mutiso, et al., Umbilical endometriosis: a case series, *J. Med. Case Rep.* 14 (2020) 142.
- [15] C.I. Theunissen, F.F. IJpma, Primary umbilical endometriosis: a cause of a painful umbilical nodule, *J. Surg. Case Rep.* 2015 (3) (2015), rjv025.
- [16] K.T. Chew, S. Norsaadah, Suraya, Primary umbilical endometriosis successfully treated with dienogest, *Horm. Mol. Biol. Clin. Invest.* 29 (2) (2017) 67–69.

- [17] S. Egin, B.A. Pektaş, S. Hot, V. Mihmanlı, Primary umbilical endometriosis: a painful swelling in the umbilicus concomitantly with menstruation, *Int. J. Surg. Case Rep.* 28 (2016) 78–80.
- [18] A. Fancellu, A. Pinna, A. Manca, et al., Primary umbilical endometriosis - case report and discussion on management options, *Int. J. Surg. Case Rep.* 4 (12) (2013) 1145–1148.
- [19] F. Akhter, R. Mallick, E. Ball, Umbilical endometriosis: case report and review of current management, *Obstet. Gynaecol. Res.* (2018) 072–074.